ESMS
European Society for Micrographic Surgery

Mohs surgery for the nail unit

olivier.cogrel@chu-bordeaux.fr

Dermatologic surgery, Mohs surgery and lasers unit

CHU Bordeaux, France

université de BORDEAUX

GROUPE CHIRURGICAL
Société Française de Dermatologie

C·H·U
Hôpitaux de Bordeaux

- Squamous cell carcinoma +++
- Acral lentiginous melanoma

  Lichte et al. Acral lentiginous melanoma: conventional histology vs. three-dimensional histology. Br J Dermatol. 2009

- Glomus tumor

Nail unit is a rare target for SCC

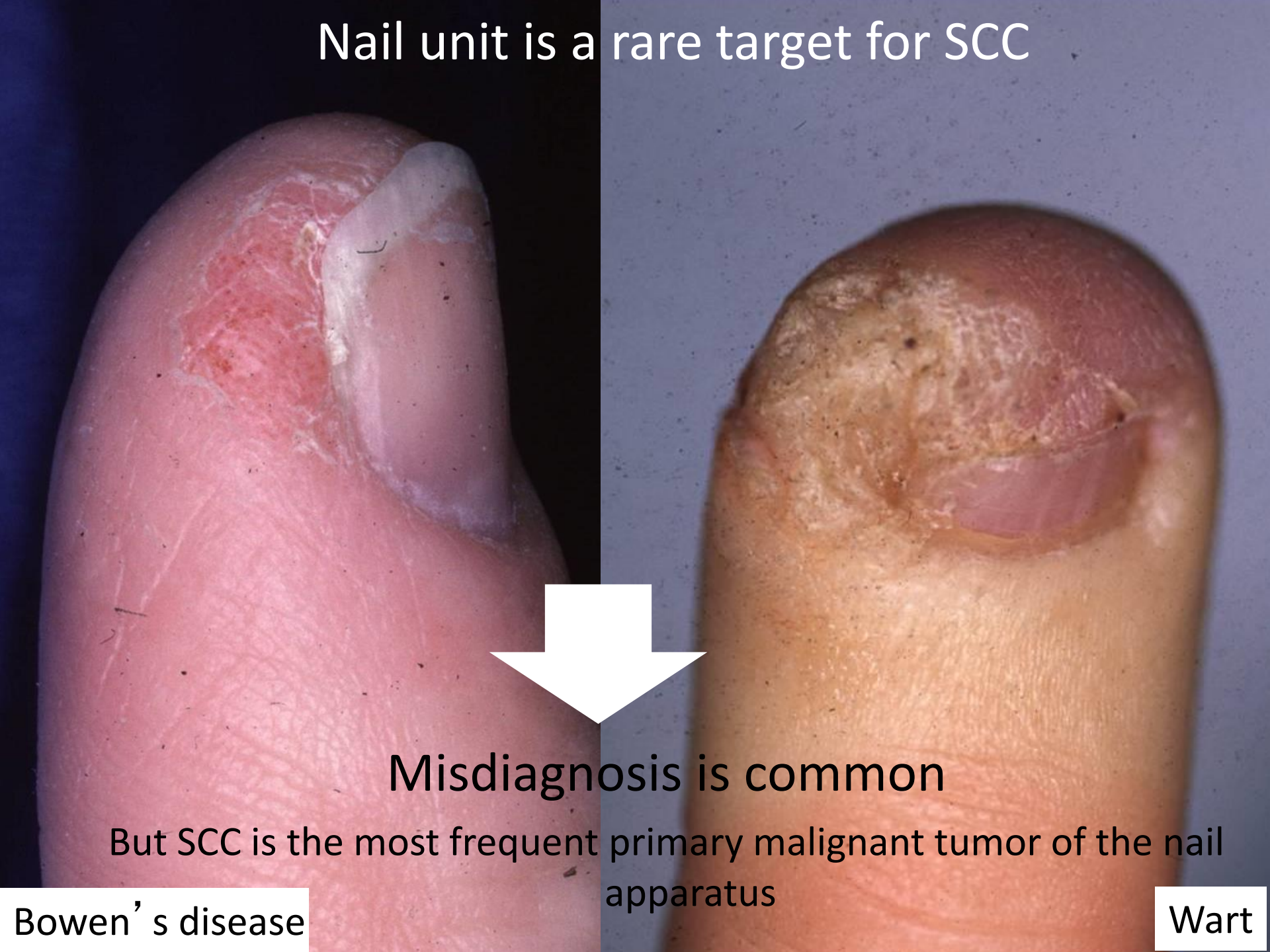

A retrospective study of squamous cell carcinoma of the nail unit diagnosed in a Belgian general hospital over a 15-year period

J Am Acad Dermatol 2013; 69:253-61.

Pauline Lecerf, MD, Bertrand Richert, MD, PhD, Anne Theunis, MD, and Josette André, MD
Brussels, Belgium

- 58 cases between 1995 to 2011
- Mean age of diagnosis: 60 yo
- Male predominance (72,5% of cases)
- Hand > Foot+++

Table I. Clinical and pathological data

No. of patients	51
No. of SCCnu	54
Sex	Male: 37 (72.5%)
	Female: 14 (27.5%)
Age	60.8 y (21-83 y)
Location	Foot: 1
	Hand: 53
	Right hand: 33 (62.3%)
	Left hand: 20 (37.7%)
Pathological findings	Location within nail apparatus
	Nail bed: 31 (57.4%)
	Periungual area (folds and grooves): 17 (31.5%)
	Both (nail bed and periungual area): 6 (11.1%)
	Degree of invasion
	In situ: 34 (63%)
	Microinvasive: 3 (5.5%)
	Invasive: 17 (31.5%)
	Depth of invasion: 1.5-8 mm
Osteolysis on x-ray	1/14 cases (7%)

SCCnu, Squamous cell carcinoma of nail unit.

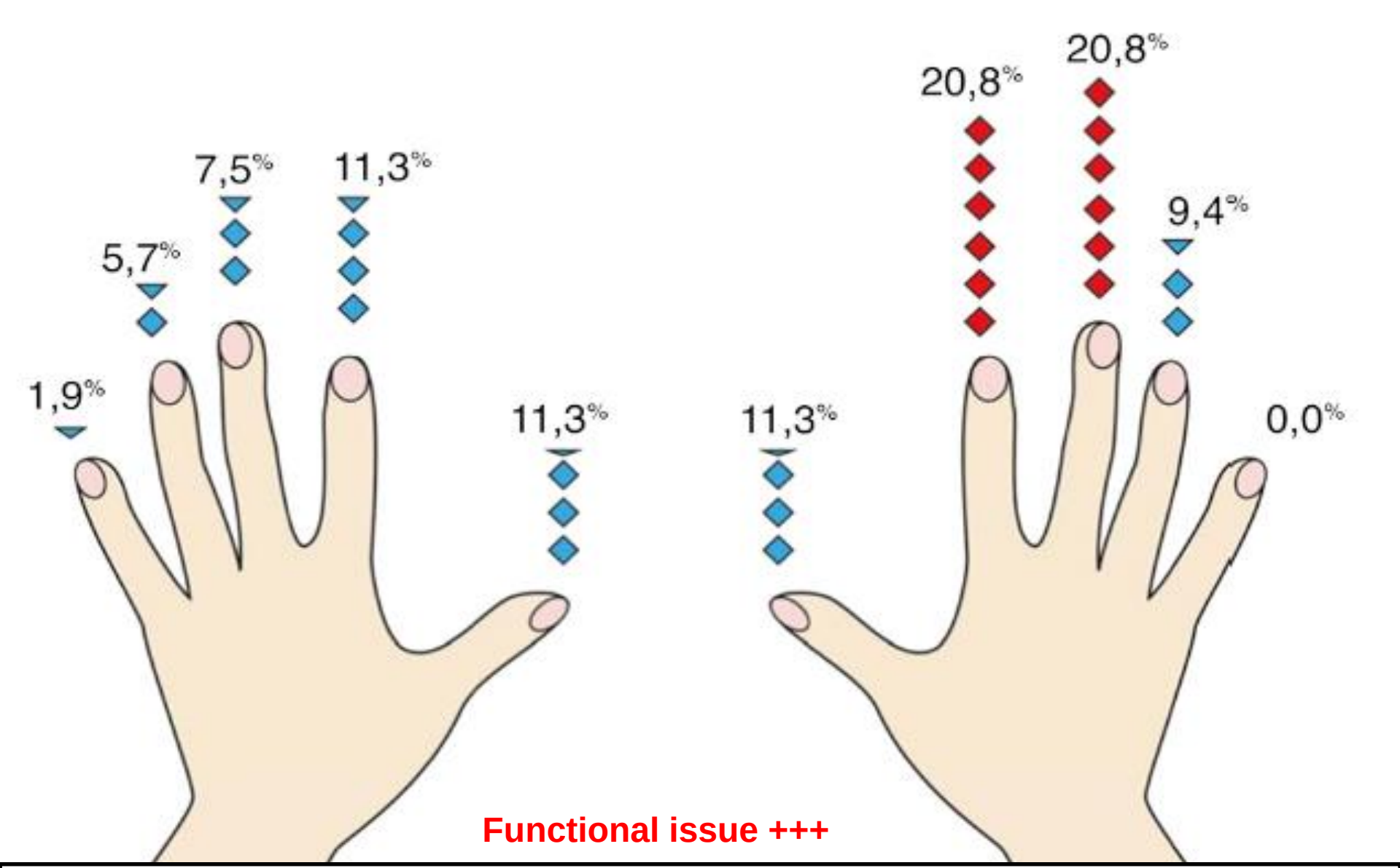

Tumors are located usually on the dominant hand
and the middle fingers are at highest risk

ORIGINAL ARTICLES

A Retrospective Study of Nail Squamous Cell Carcinoma at 2 Institutions

Nikki Tang, MD,* Mary E. Maloney, MD,† Ashlynne H. Clark, MD,‡ and Nathaniel J. Jellinek, MD†‡§

Dermatol Surg 2016;42:S8–S17

- Tobacco represents a **significant risk factor**, particularly when compared to a control adult population (p <.01).

Tobacco smoking is cofactor of HPV +++ (cervical neoplasia)

Nail unit SCC: a distinctive type that differs from other variants?

- Very slowly growing tumor
- In situ +++ (Bowen’s disease)
- But BD behaves more aggressively in the nail tissues and displays focally features of invasive SCC
- Invasive SCC is less likely to metastasize than other sites

- Currently, no standardized approach to therapy for SCC has been established



Mohs micrographic surgery : a gold standard?

- Achieve high cure rates
- Spare univolved skin
- But no comparative trial has been published

Several features must be pointed out to propose optimal treatment

1- Extent and location of the SCC (median or lateral part)

Typical erythematous scaly or verrucous plaque

- SCC develops usually from the epithelium of the lateral nail fold with a progressive periungual involvement

1- Extent and localization of the SCC

(median or lateral part)

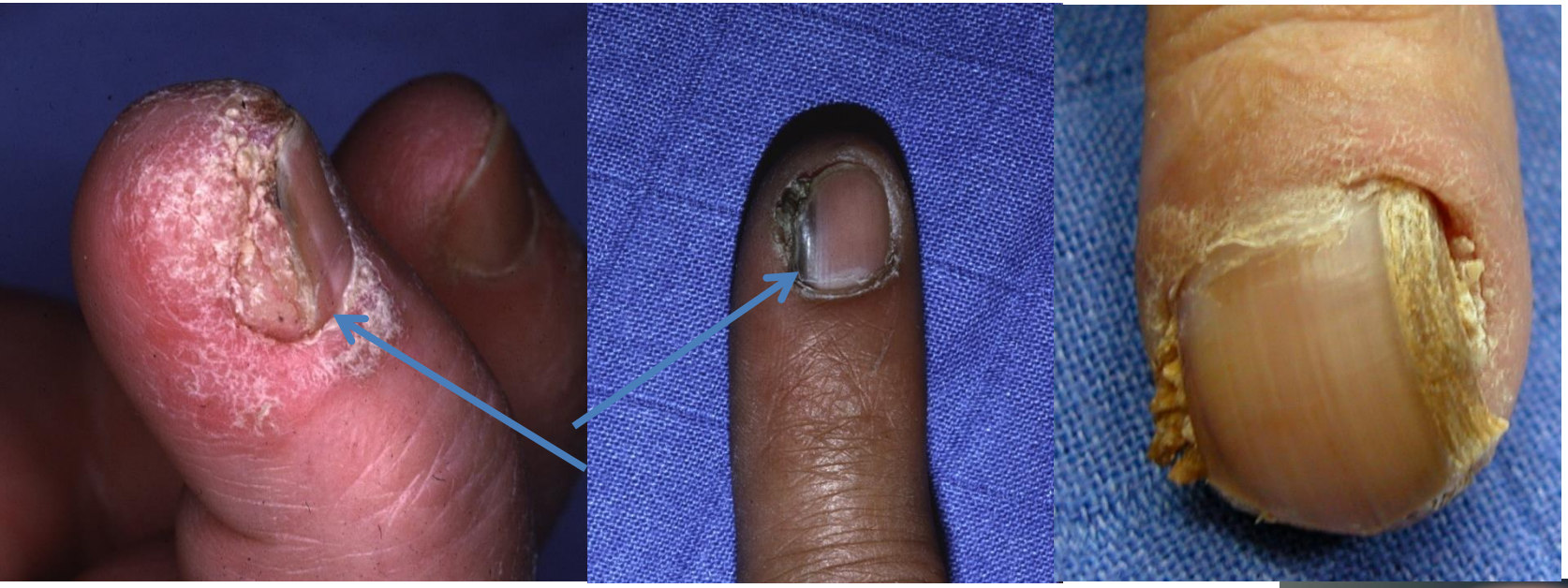

Then extension to the nail bed and matrix and when matrix is involved there is frequently a pigmented nail streak before nail plate dysrophy

1- Extent and localization of the SCC (median or lateral part)

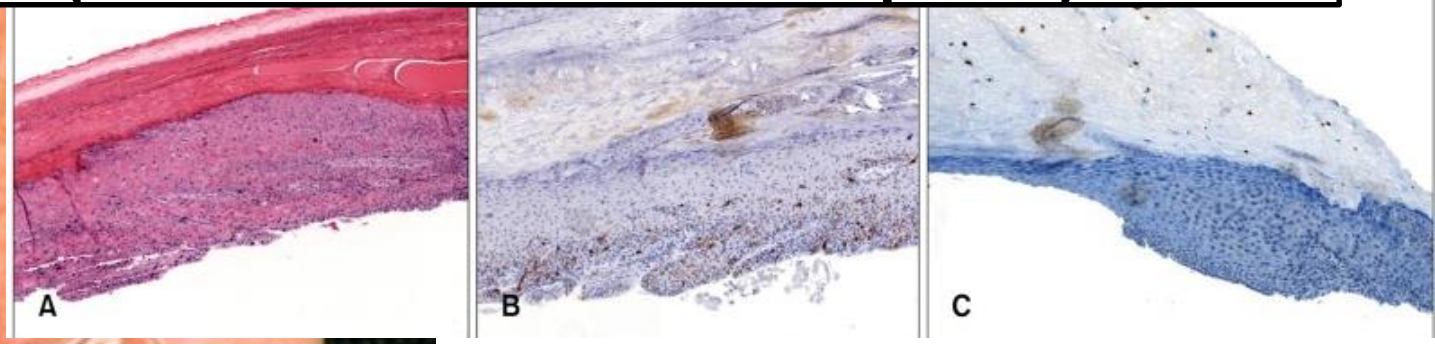

Ann Dermatol. 2013 Aug;25(3):378-9. doi: 10.5021/ad.2013.25.3.378. Epub 2013 Aug 13.

Longitudinal melanonychia on the lateral side of the nail: a sign of Bowen disease associated with human papillomavirus.

Park SW, Lee DY, Mun GH.
Department of Dermatology, Samsung Medical Center, Sungkyunkwan University School of Medicine, Seoul, Korea.

1- Extent and localization of the SCC

(median or lateral part)

- Erythronychia is a manifestation of BD and suggests a localized medial involvement from the matrix to the hyponychium

1- Extent and localization of the SCC

(median or lateral part)

Subungual involvement presents with onycholysis and when clipping away the nail plate there is frequently an oozing tumor

2- Depth of the SCC

Ulceration, bleeding, nodule formation or pain

Invasive SCC

X ray or MRI if possible

2- Depth of the SCC

- Evaluation of the depth of the tumor in the biopsy specimen
- In the study of Dalle et coll, the depth of the initial tumor was > 1 mm in all the recurrent cases

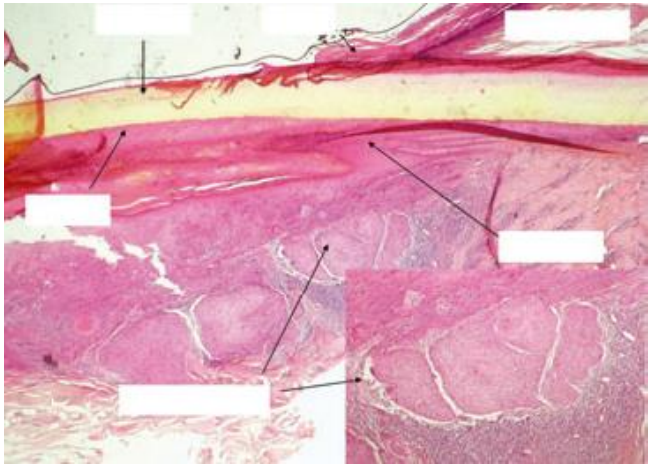

Dalle et al. Squamous cell carcinoma of the nail apparatus : clinicopathological study of 35 cases. Br J Dermatol 2007;156:871-874

Biopsy: amelanotic ALM 10 mm

3- Presence of Papillomavirus

- HPV are implicated in induction of subungual SCC especially in immunocompromised patients
- Clinical and histological continuum between warts and SCC in these patients
- Careful evaluation is required
- In the study of Alam, 26% of reccurence rate in 21 patients treated by MMS (vs 13 %)

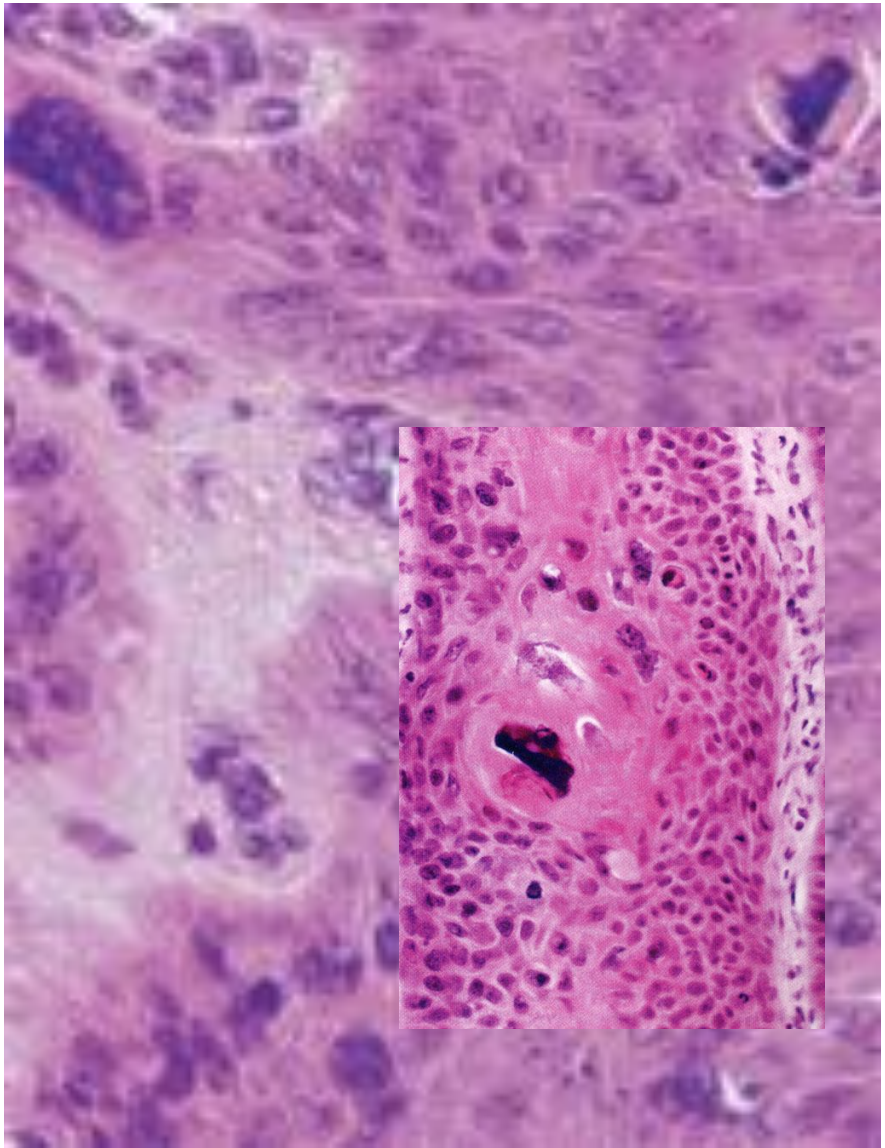

Human papillomavirus-associated digital SCC. Alam et al J Am Acad Dermatol 2003

Is there any place for distal phalanx amputation?



Owing to its frequent superficial spreading and finger nail location, conservative and functional treatment should always be considered even in microinvasive or invasive SCC

Digital amputation

- In case of preoperative evidence of bone infiltration (X-Ray, MRI)
- If deep margin after wide surgical excision is invaded
- And sometimes in case of exophytic or extensive soft tissue involvement

Can non surgical procedures be proposed?



Only for limited and superficial tumor
Dont provide histological control +++

For those who hate surgery !!! At their own risks…

- BD have been treated by curettage or electrodesiccation in a very few selected cases

Coskey et al Arch Dermatol 1972; 106:79-80

- The use of 5 FU + keratolytic agent has been effective in one case of BD of the nail bed (although follow up was only one year)

Defiebre et al J Hand Surg 1978; 3:184-6

Carbon dioxide laser ablation

Gordon et al Dermatol surg 1996; 22:723-8

- 5 patients with BD of the distal digit 2 of whom had involvement of the nail unit
- One of these patients developed recurrence after 5 months, the other was clinically clear of BD (only one year of follow up)

Photodynamic therapy

- May have an additional role as it has been shown to be an effective treatment for common viral warts and could reduce any remaining high-risk HPV infected tissue

Usmani et al J Am Acad Dermatol 2005; 53: S273-6

- 66 year old man treated with 2 cycles of topical ALA-PDT 1 month apart.
- Nail plate was avulsed under ring block local anesthesia 2 days before PDT to allow access to nail bed and matrix tissue
- 20 % ALA emulsion was applied on nail bed for 4 hours then irradiation was performed with a red light under local anesthesia

The nail regrew normally and 30 months after treatment there was no clinical evidene of recurrence

Imiquimod

- Acts as an immunomodulator due to its capacity to induce cytokine production, effectiveness in periungual warts has been showned in one open trial

Micali G et al J Dermatol Treat 2003

- But in only 2 cases of Bowen's disease of the nail : 1 case with HPV 73 and on a reccurent case (1 / day

Weisenseel P et al Hautarzt 2006

Lafitte et al Ann Dermato Venereol 2003

- Should be considered as un adjuvant treatment in case of HPV associated SCC

What is the place for Mohs Micrographic surgery?

Mohs Micrographic surgery

- MMS has been evaluated for subungual BD and SCC and provides a high cure rate (96 % in 80 cases in *Zaiac Dermatol surg 2001*)

Australasian Journal of Dermatology

Australasian Journal of Dermatology (2012) 53, 123–127 doi: 10.1111/j.1440-0960.2011.00815.x

CASE SERIES

Mohs' micrographic surgery as treatment for squamous dysplasia of the nail unit

Lauren Cordelia Young, Alana Jane Tuxen and Greg Goodman

Skin and Cancer Foundation, Melbourne, Victoria, Australia

14 patients traités
13 cicatrisation dirigée
78 % de rémission complète

Mohs Surgery for Squamous Cell Carcinoma of the Nail Unit: 10 Years of Experience

Emi Dika, MD, PhD, Pier Alessandro Fanti, MD, Annalisa Patrizi, MD, PhD, Cosimo Misciali, MD, Sabina Vaccari, MD, and Bianca Maria Piraccini, MD, PhD*

Dermatol Surg 2015

- Review the long-term outcome of patients affected by SCC who underwent MMS
- 63 cases/ 43 MMS (2005-2012, in Bologna):
  - Micro-invasive SCC: 5 cases
  - In-situ SCC: 7 cases
  - **Invasive SCC: 45 cases**

Mohs Surgery for Squamous Cell Carcinoma of the Nail Unit: 10 Years of Experience

Emi Dika, MD, PhD, Pier Alessandro Fanti, MD, Annalisa Patrizi, MD, PhD, Cosimo Misciali, MD, Sabina Vaccari, MD, and Bianca Maria Piraccini, MD, PhD*

Dermatol Surg 2015

- 43 patients underwent MMS
  - 36 patients: no bone involvement; clear of tumor after 1 to 4 sessions
  - 5 patients: tumor cells seen at the periostium level > curetage and careful follow-up
  - Bone involvement: disarticulation
  - Healing by secondary intention in the majority of cases
  - Recurrence rate: **3,5%**

Mohs Surgery for Squamous Cell Carcinoma of the Nail Unit: 10 Years of Experience

Emi Dika, MD, PhD, Pier Alessandro Fanti, MD, Annalisa Patrizi, MD, PhD, Cosimo Misciali, MD, Sabina Vaccari, MD, and Bianca Maria Piraccini, MD, PhD*

- MMS allows the evaluation of periostal invasion
- MMS does reduce the number of unnecessary amputation
- A decision to amputate should be performed after failure of MMS to clear the tumor

ORIGINAL ARTICLES

A Retrospective Study of Nail Squamous Cell Carcinoma at 2 Institutions

Nikki Tang, MD,* Mary E. Maloney, MD,† Ashlynne H. Clark, MD,‡ and Nathaniel J. Jellinek, MD†‡§

Dermatol Surg 2015

- 35/42 treated by MMS
- Recurrence rate: **9%**
- 2 main growth pattern:
  - in the lateral sulcus, SCC tend to invade deeply and proximally requiring extensive and soft tissue excision. Extension follows the lateral phalanx inimately associated with the bone but usually without direct invasion
  - Over the midline, tumors (invasive or in situ) grows downward toward the dorsal phalanx and required removal of the periostum to clear the tumor

Mohs Micrographic surgery: limits

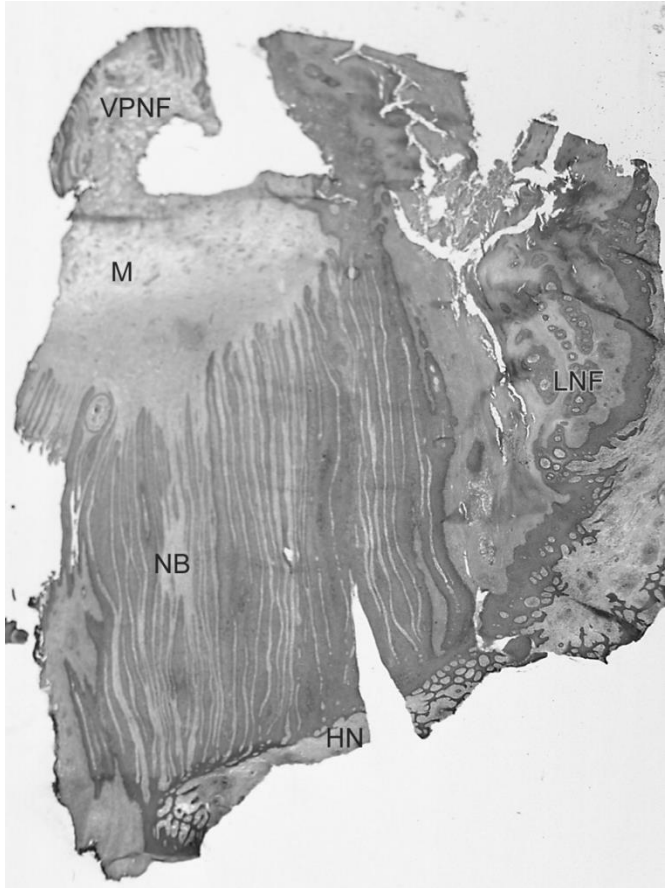

- The nail is a very challenging location for Mohs surgery because of its unique anatomical and histological characteristics
- Difficult to obtain a good horizontal section
- Those horizontal sections don't provide a good evaluatation of the depth of the tumor

Mohs Micrographic surgery: limits

- Moreover, complete extirpation of the SCC cannot ensure the elimination of HPV for the area of the tumor or its surroundings
- At last, conservation of a small part of nail is often found to be a poor benefit to the patient

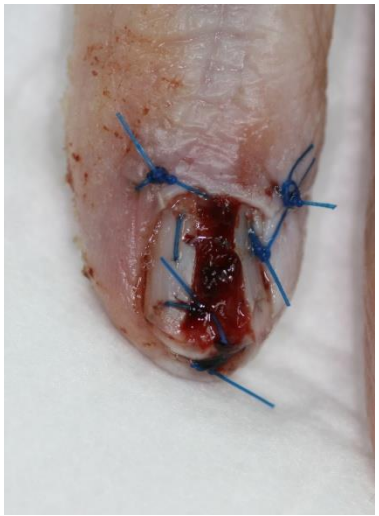

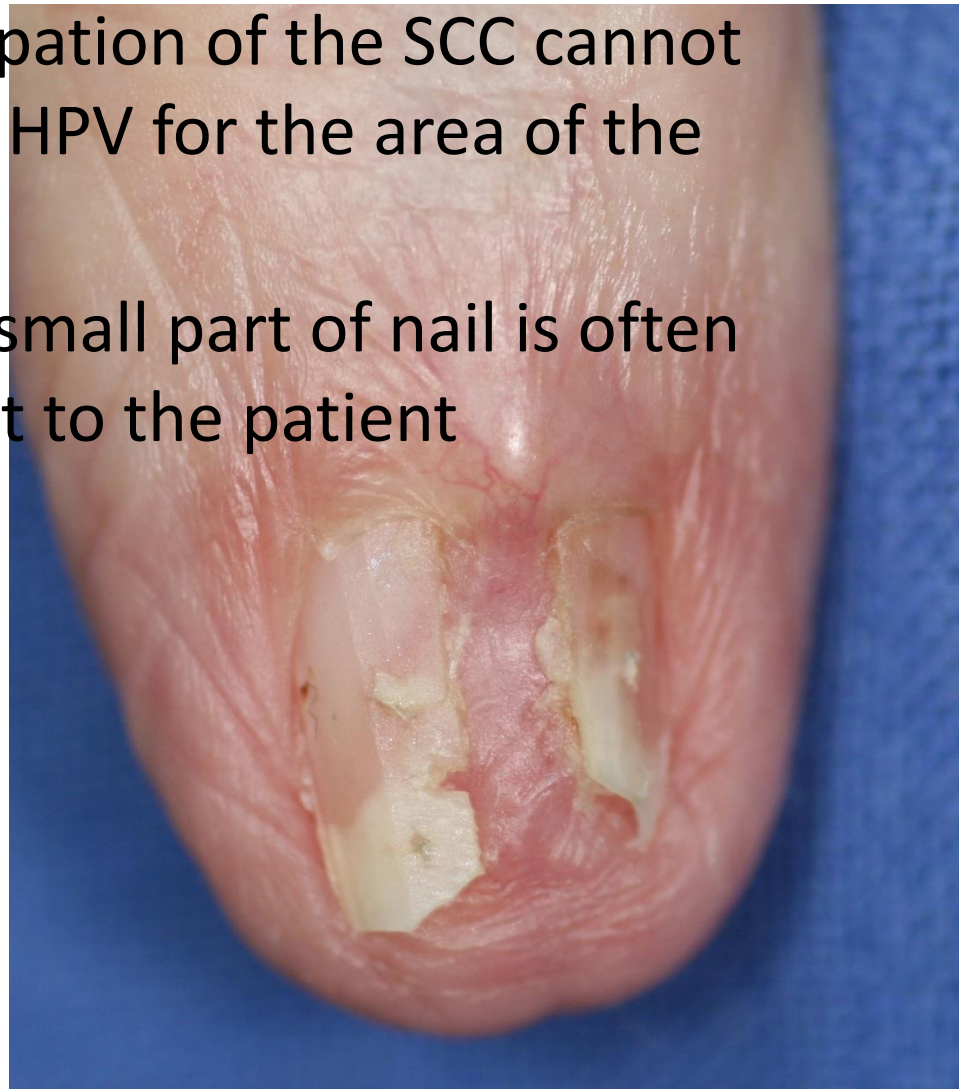

Squamous cell carcinoma

biopsy X-Ray +/- MRI

Bone invasion

No bone invasion

Deeply Invasive SCC

Digital amputation

Micro- invasive or in situ SCC

Functionnal TTT

Limited excision

Tr lateral and < 50% nail

Recurrence 56%

but No control of the margin

Dalle et al. Br J Dermatol 2007;156:871-874

Complete avulsion of the nail apparatus

Tr median <u>or</u> > lateral 50%

Recurrence 5%

Delay of recurrence ranging from 6 to 36 months

In situ SCC , micro invasive or invasive SCC without bone alterations

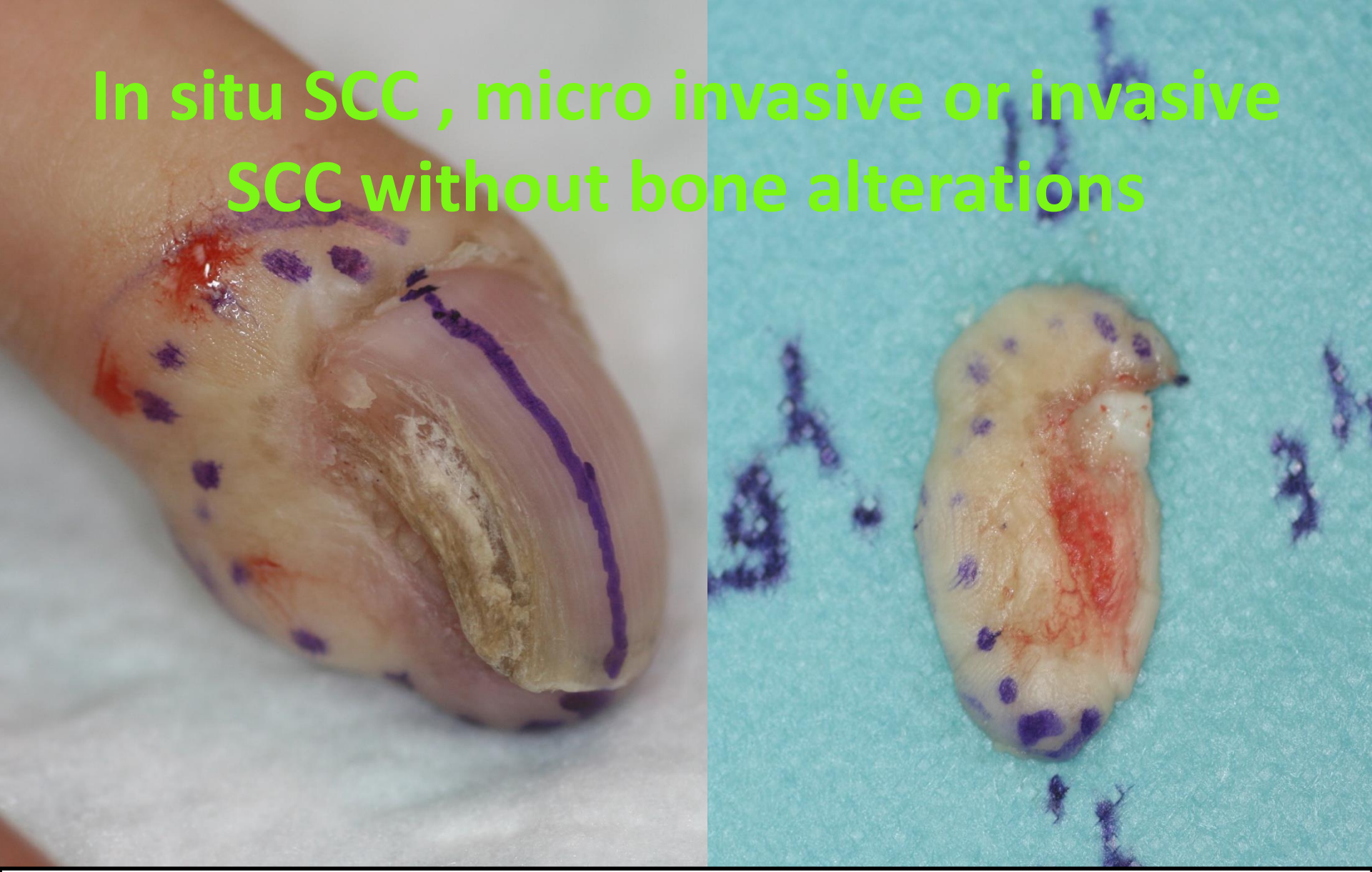

- Mohs frozen sections or 3 dimensional histology

Do we need to perform nail plate avulsion before mohs micrographic surgery for malignant tumors of the nail unit?

Frozen sections for nail surgery: avulsion is unnecessary
Jellinek NJ, Cordova KB
Dermatol Surg 2013 ; 39 :315-316.

"En bloc" excision as it is done for lateral longitudinal nail biopsy. Nail plate is previously softened by soaking the digit for at least 15 minutes. The tissue is laid flush so that the plate and attached bed and matrix epithelium are mounted en face.

Yes for limited lateral in situ SCC

Preserve superficial epithelial layers of the nail bed ans allows an entire surgical margin examination

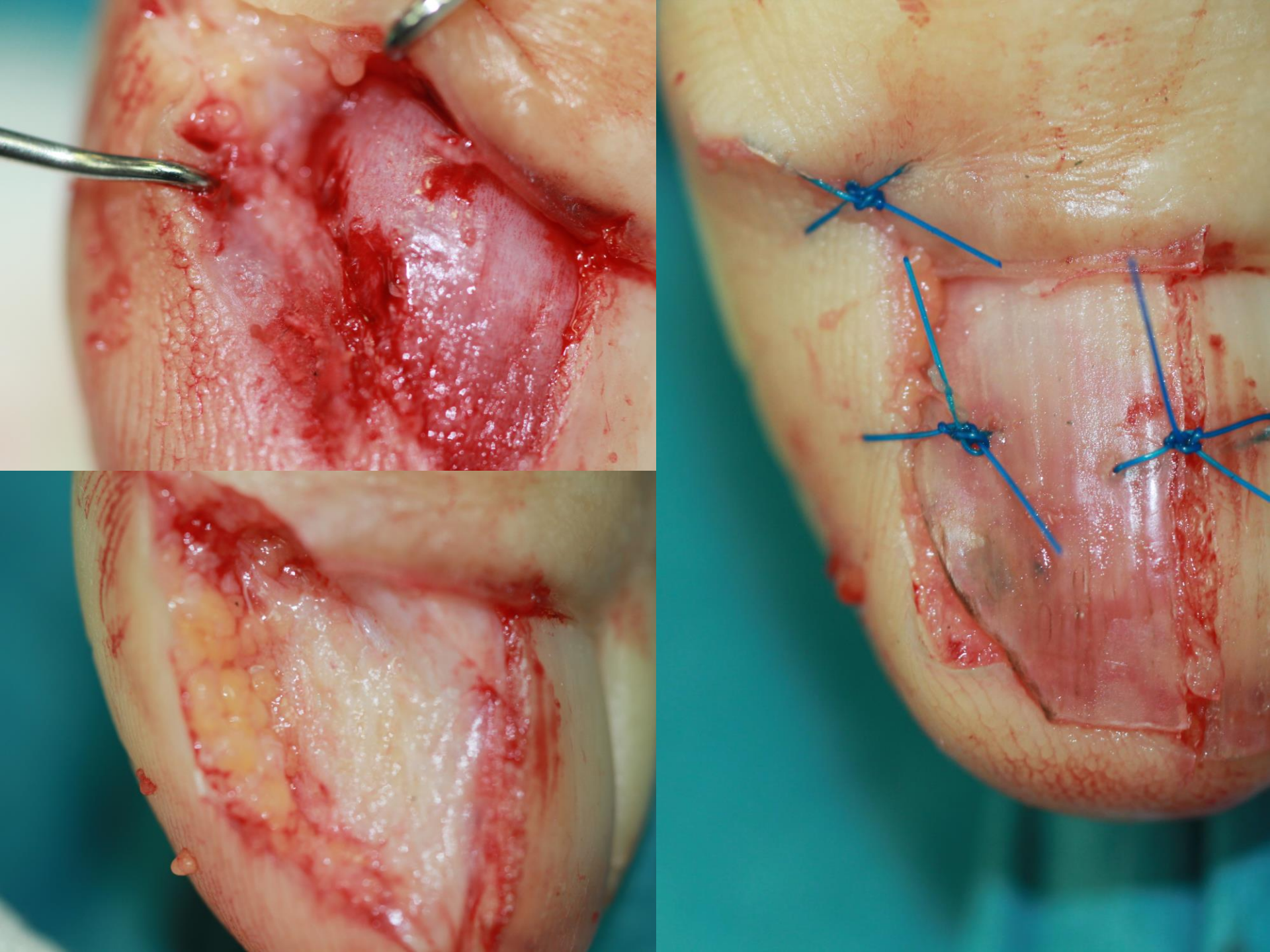

First step

Second step

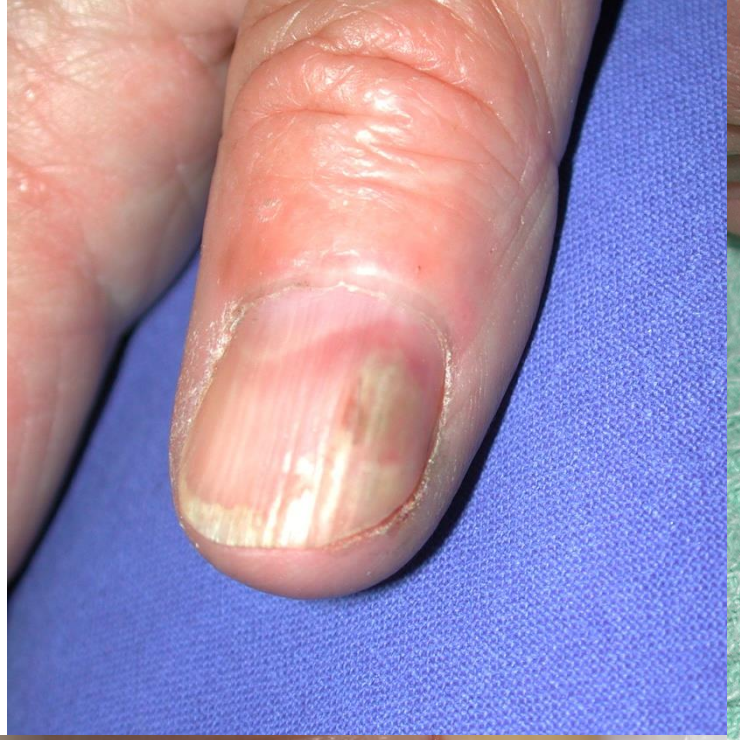

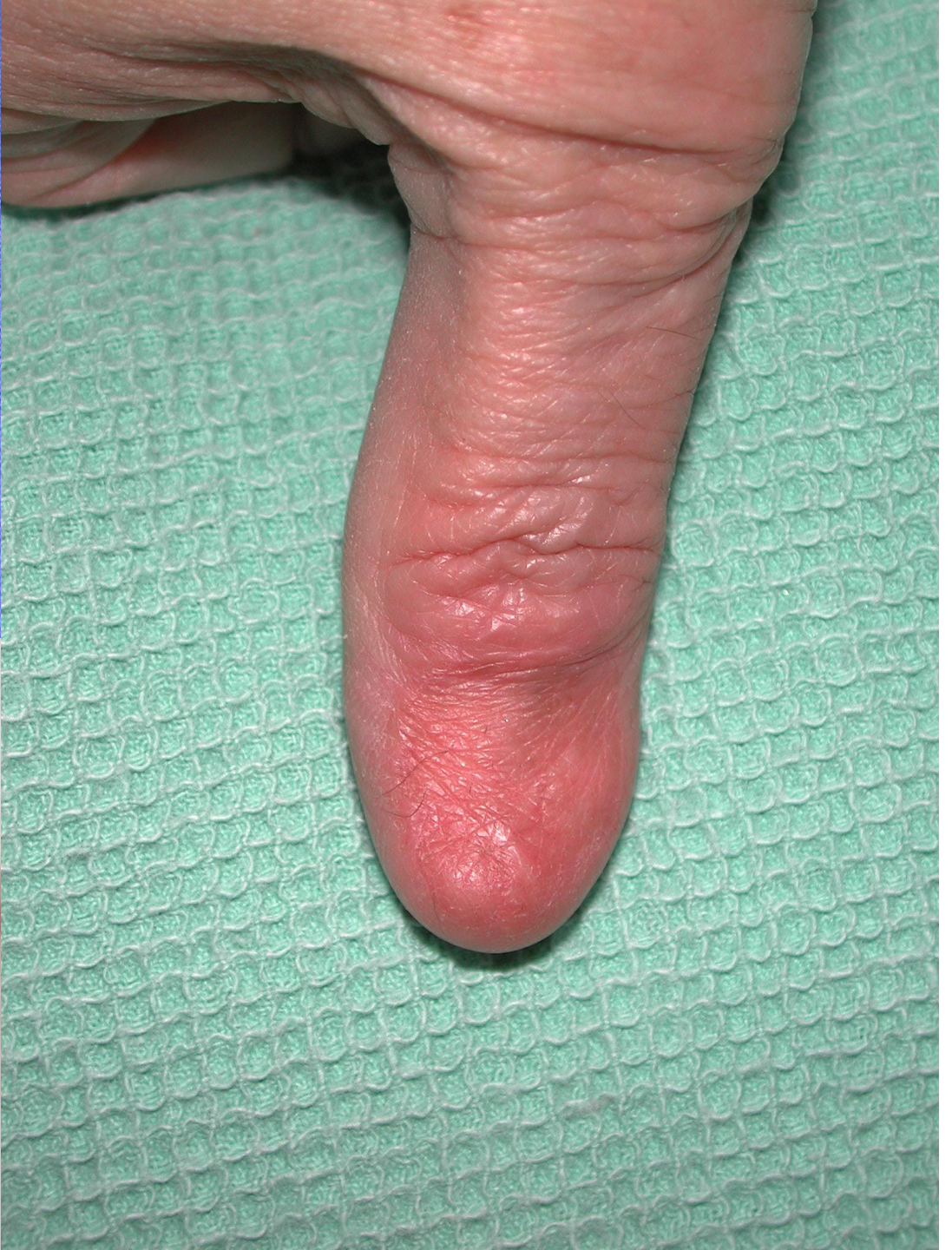

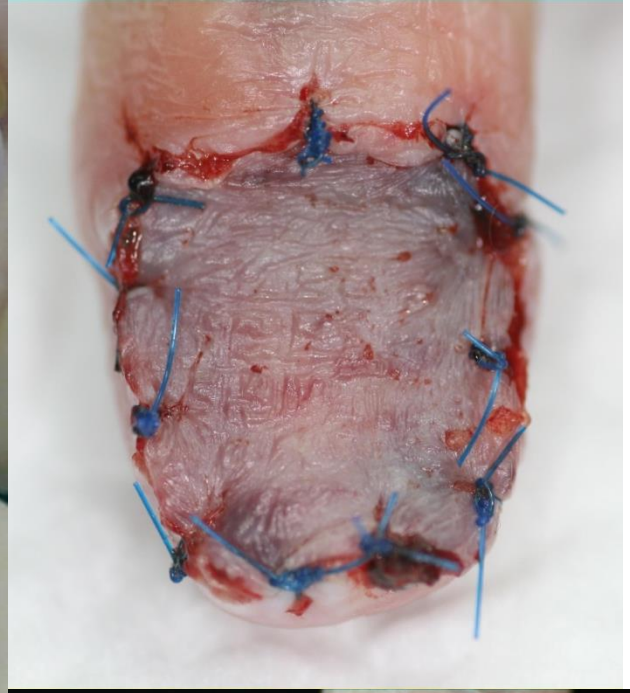

Ex: 0
Se: 0/1
Im: 3/4
Mag: 1.0x
W:255 L:127

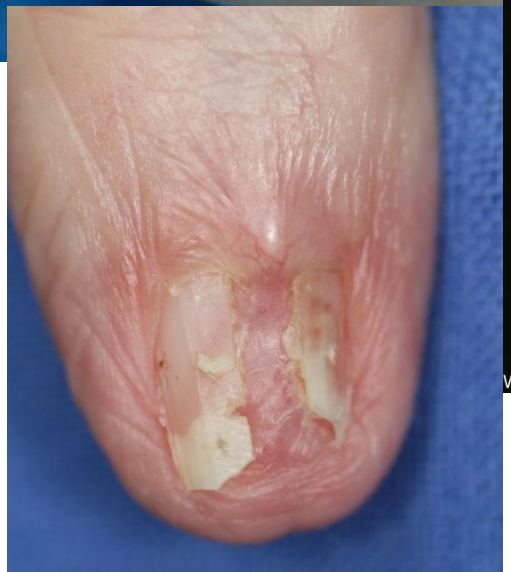

TAKE HOME MESSAGE

1. SCC is one of the most frequent malignant tumor of the nail (in situ ++)
2. Functionnal Surgery is the gold standard even for invasive SCC
3. Distal amputation for advanced SCC or with bone invasion
4. Complete ablation of the whole nail apparatus is better in case of medial or large tumor with good cosmetics results
5. Limited excision with histological control of the margin in case of limited tumor
6. Imiquimod should be evaluated in case of HPV associated SCC

ESMS
European Society for Micrographic Surgery

Thank you for your attention

olivier.cogrel@chu-bordeaux.fr

Dermatologic surgery, Mohs surgery and lasers unit

CHU Bordeaux, France

université de BORDEAUX

GROUPE CHIRURGICAL
Société Française de Dermatologie

C·H·U
Hôpitaux de Bordeaux